

# Use of Biologics as an Adjunct Therapy to Arthroscopic Surgery for the Treatment of Femoroacetabular Impingement

## A Systematic Review

Patrick G. Robinson,<sup>\*†</sup> MBChB, MRCS(Ed), Iain R. Murray,<sup>†</sup> MBChB, PhD, FRCS(Tr&Orth), Julian Maempel,<sup>‡</sup> MD, MSc, FRCS(Tr&Orth), Conor S. Rankin,<sup>†</sup> MBChB, David Hamilton,<sup>†</sup> PhD, and Paul Gaston,<sup>†</sup> MBChB(Hons), FRCS(Tr&Orth)

*Investigation performed at Department of Trauma and Orthopaedic Surgery, University of Edinburgh, Edinburgh, UK*

**Background:** There has been a recent increase in the use of biologics in hip arthroscopy to assist in the management of femoroacetabular impingement (FAI).

**Purpose:** To analyze the current use of biologics for the treatment of FAI and its associated lesions.

**Study Design:** Systematic review; Level of evidence, 4.

**Methods:** A search of the PubMed, Medline, and EMBASE databases was performed in March 2019 with use of the PRISMA (Preferred Reporting Items for Systematic Reviews and Meta-Analyses) guidelines. The criterion for inclusion was observational, published research articles studying the therapeutic use of biologics as an adjuvant therapy during arthroscopic surgery for FAI; treatments included bone marrow aspirate concentrate, mesenchymal stem cells (MSCs), platelet-rich plasma (PRP), hyaluronic acid, growth factors, and autologous chondrocyte implantation (ACI) or autologous matrix-induced chondrogenesis (AMIC).

**Results:** There were 9 studies that met the inclusion criteria, and a total of 674 patients were included across all studies. FAI was studied in all articles. Further, 7 studies (78%) also analyzed chondral injuries, and 3 studies also analyzed labral tears (33%). ACI or AMIC was used in 56% of studies and showed superior functional outcomes at short- and midterm follow-up versus debridement or microfracture. PRP did not improve the outcome of labral repairs at short-term follow-up.

**Conclusion:** The current literature regarding biologic adjuncts in hip arthroscopy is varied in quality, with only one level 1 study. The use of ACI/AMIC for medium-sized chondral lesions showed promising results in individual studies; however, these were of lower quality. To enable comparisons among future studies, investigators must ensure accuracy in the reporting of biologic preparations and formulations used and homogeneity in the type and severity of lesion treated.

**Keywords:** hip; arthroscopy; biologic healing enhancement; platelet-rich plasma

\*Address correspondence to Patrick Robinson, MBChB, MRCS(Ed), Department of Trauma and Orthopaedic Surgery, University of Edinburgh, UK. (email: patrick.robinson321@gmail.com) (Twitter: @paddy\_robinson).

<sup>†</sup>Department of Trauma and Orthopaedic Surgery, University of Edinburgh, Edinburgh, UK.

<sup>‡</sup>Department of Orthopaedic Surgery, The Royal Melbourne Hospital, Parkville, Victoria, Australia.

The authors declared that there are no conflicts of interest in the authorship and publication of this contribution. AOSSM checks author disclosures against the Open Payments Database (OPD). AOSSM has not conducted an independent investigation on the OPD and disclaims any liability or responsibility relating thereto.

The Orthopaedic Journal of Sports Medicine, 7(12), 2325967119890673

DOI: 10.1177/2325967119890673

© The Author(s) 2019

Hip arthroscopy has shown great promise for the surgical management of both intra-articular and extra-articular hip lesions.<sup>16,36</sup> In particular, arthroscopy has been shown to be an effective treatment for femoroacetabular impingement (FAI) syndrome, which is a well-recognized cause of hip pain in the young, active population<sup>15,36</sup> and the most common abnormality treated by hip arthroscopy.<sup>37</sup> Other lesions that have been treated by hip arthroscopy include ligament teres tears,<sup>4</sup> psoas tendon tears,<sup>44</sup> and osteonecrosis of the femoral head.<sup>37</sup> Labral tears, chondral injuries, and osteoarthritis can often be secondary to FAI,<sup>1,2</sup> and it is possible to treat these during hip arthroscopy by surgical techniques and/or biologics treatments.

This open-access article is published and distributed under the Creative Commons Attribution - NonCommercial - No Derivatives License (<https://creativecommons.org/licenses/by-nc-nd/4.0/>), which permits the noncommercial use, distribution, and reproduction of the article in any medium, provided the original author and source are credited. You may not alter, transform, or build upon this article without the permission of the Author(s). For article reuse guidelines, please visit SAGE's website at <http://www.sagepub.com/journals-permissions>.

Biologics have become increasingly popular in orthopaedics and sports medicine over the past 20 years.<sup>21</sup> These agents aim to provide superior clinical outcomes by optimizing and accelerating musculoskeletal tissue healing. Current biologic treatments available include bone marrow aspirate concentrate, culture-expanded mesenchymal stem cells (MSCs) and stromal cells, autologous blood products (including platelet-rich plasma [PRP]), growth factors, hyaluronic acid, and autologous chondrocyte implantation (ACI) or autologous matrix-induced chondrogenesis (AMIC). Promising results have been shown in vitro with respect to bone<sup>17</sup> and cartilage regeneration.<sup>28</sup> Results in the clinical literature have been varied; however, encouraging results have been shown in a number of randomized controlled trials in the treatment of both lateral epicondylitis<sup>13,27</sup> and fracture healing.<sup>14</sup>

Despite the recent popularization of biologics in the treatment of musculoskeletal conditions, there has been substantial heterogeneity in the reporting of the preparation, concentration, and delivery of these agents. Murray et al<sup>32</sup> presented the range of PRP concentrations in a recent review. The authors reported the concentration of PRP in current commercial systems to range from 1.7 to 9.3 times the platelet concentration of whole blood. Robinson et al<sup>42</sup> reported large variations in the source, concentration, and delivery methods of MSCs within the current orthopaedic literature.

The use of biologics in the treatment of hip joint abnormality has predominantly focused on the management of osteonecrosis of the femoral head,<sup>38</sup> often in conjunction with core decompression. A recent systematic review of treatment of osteonecrosis of the femoral head concluded that cell-based therapy was a safe treatment that provided improved clinical outcomes and reduced disease progression.<sup>39</sup> Many systematic reviews have analyzed the use of biologics in other aspects of orthopaedic surgery, including rotator cuff repair,<sup>6,18</sup> anterior cruciate ligament reconstruction,<sup>9,45</sup> and tendinopathy.<sup>3,10,23,26,35</sup> However, despite the increasing use of biologics in hip arthroscopy to treat FAI and its associated intra-articular abnormalities, no systematic reviews have analyzed all relevant studies.

The purpose of this study was to systematically review the current literature reporting the use of biologics in the management of FAI and its associated lesions and to compare the outcomes of these studies.

## METHODS

A search of PubMed, Medline, and EMBASE was performed in March 2019 in line with the PRISMA (Preferred Reporting Items for Systematic Reviews and Meta-Analyses) statement.<sup>29</sup> The study was registered using the PROSPERO international prospective register of systematic reviews.

Titles and abstracts identified were independently reviewed by 2 authors (P.G.R., P.G.), and those studies not meeting the inclusion criteria were excluded before full-text review. When the relevance of an abstract was in

doubt, the full text was subsequently reviewed. Unanimous consensus was met among the authors regarding the inclusion of proposed studies for full-text review. The studies selected for full-text review were then further evaluated against the inclusion and exclusion criteria. A search of the references was performed of the selected studies to ensure no other relevant studies were missed.

## Search Terms and Criteria for Inclusion

The criteria for inclusion were observational published research articles (randomized controlled trials, cohort, cross-sectional, or case-control studies) and case series studying the therapeutic use of biologics as adjuvant therapy to arthroscopic surgery in the management of FAI; treatments included bone marrow aspirate concentrate, MSCs, PRP, hyaluronic acid, growth factors, and ACI or AMIC. Studies were excluded if they were technical or review articles, included synthetic bone matrices or bone substitutes, or were not published in the English language. For the biologic treatments studied in this review, 6 separate searches were performed in each database. The search terms were *hip, femoroacetabular, impingement, arthroscopy, platelet rich plasma, mesenchymal stem cells, bone marrow aspirate, growth factors, hyaluronic acid, and chondrocyte implantation*. Detailed search term combinations can be found in Appendix Table A1.

## Data Extraction

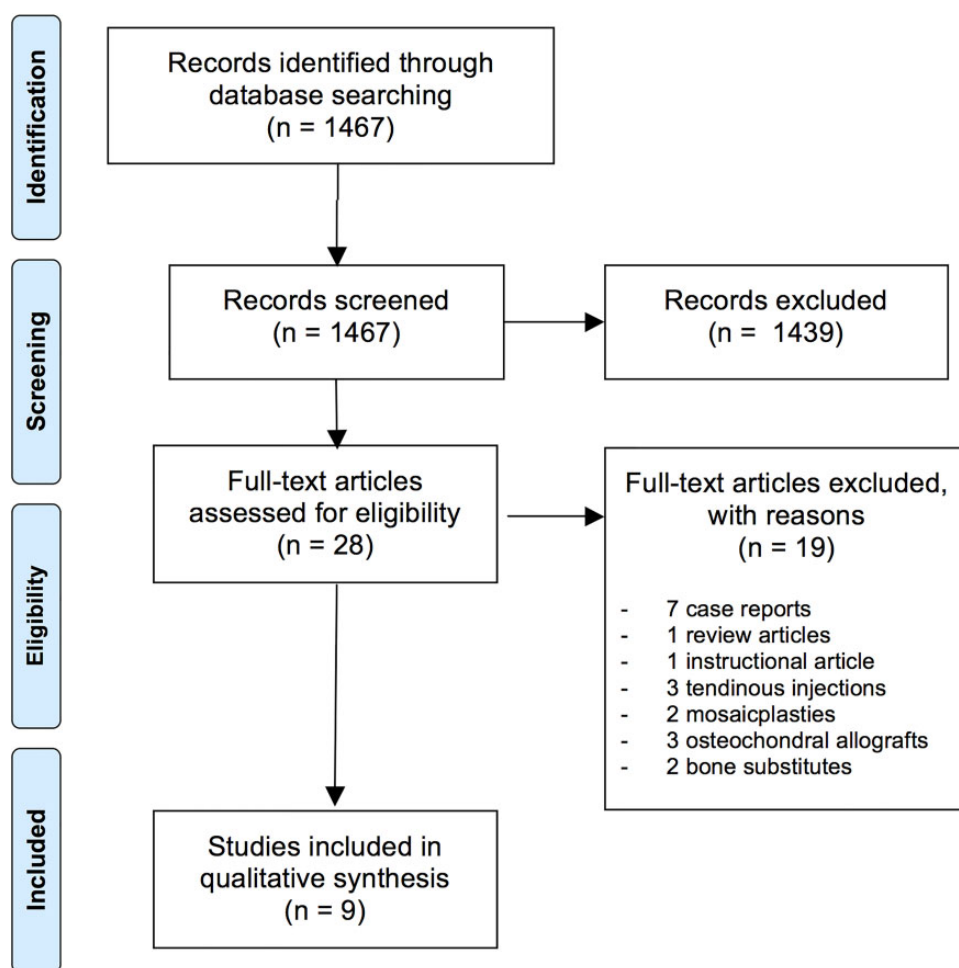
The collected data from each study included the year of publication, study type, patient age, sex, body mass index, pathologic condition, type of surgery, size and severity of the chondral lesion, severity of arthritis, biologic treatment used, follow-up, outcomes, reoperation rate, conversion to total hip arthroplasty (THA), and the level of evidence.

## Outcome Measures and Analysis

The primary objective was to report the variety of biologic treatments used and to compare clinical outcomes. Secondary objectives included reporting the spectrum of severity of the pathologic condition treated, establishing ideal biologic formulations for specific lesions, assessing complications, and analyzing the quality of the included studies. Data analysis was primarily in the form of reporting variables collected in the data extraction process, and efforts were made to consolidate data if they were comparable. A meta-analysis was not performed because of the heterogeneous nature of the data in each included paper.

## Quality Assessment

All studies were quality assessed by 2 authors (P.G.R., P.G.) using the NIH Quality Assessment Tool for Observational Cohort and Cross-Sectional Studies. The authors of the assessment tool discourage users from allocating a specific score to each study. We have not given a traditional “good,” “fair,” or “poor” rating to each study but have instead given a percentage to the number of applicable



**Figure 1.** PRISMA (Preferred Reporting Items for Systematic Reviews and Meta-Analyses) flow diagram demonstrating selection process for included studies.

questions answered “yes.” If there was disagreement regarding the scoring of a study, consensus was met after discussion among both assessors.

## RESULTS

In the initial search of databases and reference lists, 1467 articles were identified. After initial screening of titles and abstracts, 28 articles met the inclusion criteria for review. On full-text screening, a further 19 studies were excluded (Figure 1). A final 9 studies met the inclusion criteria and are described in Table 1. The year of publication ranged from 2012 to 2016. The studies included 3 case series, 1 retrospective cohort study, 3 prospective cohort studies, and 2 randomized controlled trials. There were 3 high-level studies: 1 study was level 1 and 2 studies were level 2. A total of 674 patients were included across all studies. The mean patient age was 37.6 years (range, 16-60 years), and the overall mean ratio of male to female participants was 1 to 1.2. The mean length of follow-up was 34 months (range, 12-74 months). There were 2 studies that reported the mean body mass index, which was 25.5 (range, 25-26).

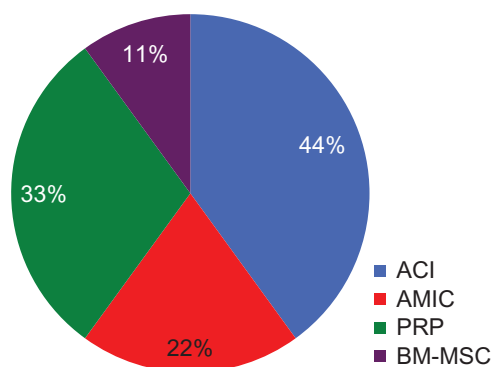
All studies used FAI as their minimum inclusion criterion, which included assessment with plain radiographs and magnetic resonance imaging (MRI). Biologic therapy was used in the adjuvant treatment of labral repairs in 3 studies (33%), chondral injuries in 8 studies (89%), and osteoarthritis in 1 study (11%). Of the studies examining chondral injuries, all reported injuries to the acetabulum, and 2 studies also examined femoral head defects (Table 2). ACI was used in 4 studies (44%), AMIC in 2 studies (22%), and PRP in 3 studies (33%). Bone marrow-derived MSCs (BM-MSCs) were used in 1 study (11%). Further, 1 study used both AMIC and ACI.

Details of the surgical techniques used to treat FAI were described in 7 studies (78%). The mean proportion of patients receiving acetabuloplasty was 37.8% (range, 0%-100%), and the mean proportion receiving femoroplasty was 60.8% (range, 38%-100%). There were 5 studies (56%) that reported the method used to treat labral tears. Redmond et al<sup>41</sup> performed a randomized controlled trial comparing PRP versus placebo in 306 patients with labral tears. Labral repair was performed in 57% of patients, and 32% underwent labral debridement. This was the only

TABLE 1  
Patient Demographics<sup>a</sup>

Lead Author	Journal	Year	No. of Patients	Gender, n	Mean Age (Range)	Follow-up, mo	Chondral Grading	OA Severity
Fickert <sup>8</sup>	<i>Arch Orthop Trauma Surg</i>	2014	6	5 M, 1 F	33 (25-45)	12	ICRS 3 & 4	KL <2
Fontana <sup>12</sup>	<i>Bone Joint J</i>	2015	147	91 M, 56 F	NR	60	OB 3 & 4	Tönnis grade <2
Fontana <sup>11</sup>	<i>Arthroscopy</i>	2012	30	12 M, 18 F	41 (20-53)	74	OB 3 & 4	Tönnis grade 2
Körsmeier <sup>19</sup>	<i>Knee Surg Sports Traumatol Arthrosc</i>	2016	16	14 M, 2 F	31 (20-47)	16	OB 3 & 4	NR
LaFrance <sup>20</sup>	<i>J Hip Preserv Surg</i>	2015	35	NR	35 (18-63)	12	NA	>1 mm joint space
Mancini <sup>24</sup>	<i>Int Orthop</i>	2014	57	25 M, 32 F	36	60	OB 3 & 4	Tönnis grade <2
Mardones <sup>25</sup>	<i>Muscles Ligaments Tendons J</i>	2016	20 (29 hips)	10 M, 10 F	51 (39-60)	24	OB 3 & 4	Tönnis grades 2 & 3
Rafols <sup>40</sup>	<i>Arthroscopy</i>	2015	57	30 M, 27 F	35 (16-52)	24	NA	Tönnis grade <2
Redmond <sup>41</sup>	<i>Arthroscopy</i>	2015	306	103 M, 203 F	36	24	NA	NR

<sup>a</sup>F, female; ICRS, International Cartilage Repair Society classification; KL, Kellgren-Lawrence score; M, male; NA, not applicable; NR, not recorded; OA, osteoarthritis; OB, Outerbridge classification.



**Figure 2.** Representation of the types of biologics used in the included studies. Note that Mancini and Fontana<sup>24</sup> used 2 biologics (AMIC vs ACI). ACI, autologous chondrocyte implantation; AMIC, autologous matrix-induced chondrogenesis; BM-MSC, bone marrow-derived mesenchymal stem cells; PRP, platelet-rich plasma (PRP).

study to report whether capsular closure or repair was performed.

### Injury and Osteoarthritis Severity

The presence of hip osteoarthritis was reported in 8 of the included studies (89%). Tönnis grading was used in 5 studies (56%), and the Kellgren-Lawrence classification was used in 1 study (11%). A further study excluded patients with “severe osteoarthritis” but did not report how the investigators defined this. LaFrance et al<sup>20</sup> did not use a recognized classification but did exclude patients with less than 1 mm of joint space on anteroposterior or lateral hip radiographs. With regard to the severity of the osteoarthritis, 4 studies included patients with grade 2 or lower, on the Tönnis grading system, and 1 study included grades 2 and 3. The study using the Kellgren-Lawrence classification included grade 1 only.

Of the 8 studies reporting chondral injury, 4 studies (50%) reported the size of the lesions treated. The mean size was 3.4 cm<sup>2</sup> (range, 2-8 cm<sup>2</sup>) (Table 2). The Outerbridge classification was used to grade the chondral lesions in 5 studies (56%), in which all studies included grades 3 or 4. One further study used the International Cartilage Repair Society score and included grades 3 and 4. Acetabular and femoral locations of the chondral injuries were reported in 2 studies (25%).

### Details of Biologics Used

All studies performing ACI used a 3-dimensional technique. Körsmeier et al<sup>19</sup> and Fickert et al<sup>8</sup> used 3-dimensional spheroids cultured from chondrocytes that were harvested from the femoral head-neck junction (Chondrosphere; Co.Don AG). They were delivered without the requirement for a scaffold. Fontana et al<sup>11</sup> and Mancini and Fontana<sup>24</sup> used ACI with the chondrocytes isolated adjacent to the injury site and seeded onto a polymer scaffold composed of polylactic/polyglycolic acid and polydioxanone (Bioseed-C; Biotissue AG) before reimplantation.

The timing of delivery of chondrocytes varied among the 4 studies. Fickert et al<sup>8</sup> reported chondrocyte delivery 4 to 6 weeks after harvesting. Mancini and Fontana<sup>24</sup> reported a delivery of approximately 3 weeks after harvesting, whereas Fontana et al<sup>11</sup> reported a delivery time of 2 to 6 weeks postoperatively. Körsmeier et al<sup>19</sup> reported a delivery time of 5 to 10 weeks after harvest and described 95% cell viability at the time of surgery. No study using ACI reported the concentration of the chondrocytes delivered.

Fontana and de Girolamo<sup>12</sup> and Mancini and Fontana<sup>24</sup> both analyzed the use of AMIC. Both studies used a resorbable collagen I/III matrix (Chondroglide; Geistlich AG) in a single surgical technique. Rafols et al<sup>40</sup> and Redmond et al<sup>41</sup> both used PRP intraoperatively via percutaneous intra-articular injection after wound closure. Rafols et al used activated GPS III (Biomet), which is 7 to 8 times the whole blood concentration. Redmond et al used Arthrex

TABLE 2  
Study Design, Level of Evidence, Pathologic Condition, and Biologic Used in the Included Studies<sup>a</sup>

Lead Author	Study Design	Pathologic Condition	Location	Chondral Lesion, cm <sup>2</sup> , mean (range)	Biologic	LOE
Fickert <sup>8</sup>	Case series	FAI + chondral defect	Acetabulum/ femoral head	NR	ACI	4
Fontana <sup>12</sup>	Prospective cohort	FAI + chondral defect	Acetabulum	3.6 (2-8)	AMIC vs MFx	3
Fontana <sup>11</sup>	Retrospective cohort	FAI + chondral defect	Acetabulum/ femoral head	2.6 (2-3)	ACI vs debridement	3
Körsmeier <sup>19</sup>	Case series	FAI + chondral defect	Acetabulum	4.5 (3-6)	ACI	3
LaFrance <sup>20</sup>	RCT	FAI + labral tear ± chondral defect	Acetabulum	NR	PRP vs placebo	1
Mancini <sup>24</sup>	Prospective cohort	FAI + chondral defect	Acetabulum	2.9 (2-4)	ACI vs AMIC	3
Mardones <sup>25</sup>	Case series	FAI + chondral defect or OA	NR	NR	BM-MSc	4
Rafols <sup>40</sup>	RCT	FAI + labral tear	NR	NA	PRP vs placebo	2
Redmond <sup>41</sup>	Prospective cohort	FAI + labral tear ± chondral defect	NR	NR	PRP vs LA	2

<sup>a</sup>ACI, autologous chondrocyte implantation; AMIC, autologous matrix-induced chondrogenesis; BM-MSc, bone marrow–derived mesenchymal stem cells; FAI, femoroacetabular impingement; LA, local anesthetic; LOE, level of evidence; MFx, microfracture; NA, not applicable; NR, not recorded; OA, osteoarthritis; PRP, platelet-rich plasma; RCT, randomized controlled trial.

ACP Double-Syringe system (Arthrex), which is 2 to 3 times the whole blood concentration. LaFrance et al<sup>20</sup> injected 5 mL of PRP prepared with Accelerate Concentrating System (Exactech Biologics) at the completion of the procedure after evacuation of joint fluid. The platelet concentration of this system is reported at 6 times the whole blood concentration.

Finally, Mardones et al<sup>25</sup> harvested BM-MSCs from the anterior superior iliac spine at the time of initial arthroscopy. Cells were then expanded to reach  $20 \times 10^6$  cells and checked with immunotypification via flow cytometry for MSC markers. They were then injected once a week by radioscopic guidance at the fourth, fifth, and sixth week after harvesting.

## Clinical Outcomes

The clinical outcomes of each study are described in Table 3.

## Complications

There were 6 studies that reported reoperation rates or conversion to THA. Körsmeier et al<sup>19</sup> reported a reoperation rate of 12.5% at a mean follow-up of 16 months but no conversions to THA during this time. Capsular adhesions were removed in the reoperative cases, and both patients were satisfied after repeat arthroscopy. Redmond et al<sup>41</sup> reported a reoperation rate of 10.6% in the PRP group (reasons not reported) and 6.4% in the control group ( $P = .2$ ) and a THA conversion rate of 2.9% in the PRP group and 5% in the control group ( $P = .4$ ) during their 2-year follow-up. Fontana and de Girolamo<sup>12</sup> reported no conversions to THA in the AMIC cohort and a 7.8% conversion rate in the microfracture cohort at a mean follow-up of 38 months. No reoperations or conversions to THA were reported in the studies by Fickert et al,<sup>8</sup> Mancini and Fontana,<sup>24</sup> or Fontana et al<sup>11</sup> at 12-, 60-, and 74-month follow-up, respectively. Mardones et al<sup>25</sup> did not report

any reoperations but reported a THA conversion rate of 13.8% at mean follow-up of 24 months. No complications were reported that were attributable to the delivery of the biologics.

## Quality Assessment

The results of the quality assessment of included studies can be seen in Appendix Table A1. The mean percentage of successfully answered questions from the assessment tool was 67%. The level of evidence ranged from 1 to 4. The mode level was 3.

## DISCUSSION

The most significant findings were as follows: (1) a limited number of high-level articles have reported the use of biologics in the management of FAI; (2) variation existed in the timing of delivery and concentration of biologics used; (3) the use of ACI and AMIC appeared to deliver favorable results for medium-sized chondral defects at short-term to midterm follow-up compared with debridement or microfracture; and (4) the use of PRP appeared to be ineffective as adjuvant treatment of labral tears at short-term follow-up.

Chondral injuries within the hip joint have been historically problematic to treat. However, the introduction of hip arthroscopy has allowed a spectrum of treatment options to help manage these injuries. ACI has already been proven to be an effective treatment in the short to mid term for chondral lesions ( $>2$  cm<sup>2</sup>) in the knee.<sup>5,43</sup> All the studies included in this review that used ACI to treat chondral injuries showed favorable patient-reported outcome scores when compared with preoperative scores and/or simple debridement or microfracture. Mancini and Fontana<sup>24</sup> evaluated patients up to 5 years in 3 studies analyzing the use of ACI or AMIC and showed maintained improvements in postoperative

TABLE 3  
Clinical Outcomes After Biologics Intervention in Hip Arthroscopy<sup>a</sup>

Lead Author	Clinical Outcome
Fickert <sup>8</sup>	Statistically significant improvements in postoperative mHHS (mean improvement 23.5; $P = .04$ ) and SF-36 physical score (mean improvement 45.6; $P < .01$ ) at 12 months compared with preoperative scores but no improvement in SF-36 mental score. Larger defect associated with poorer mHHS score but not lower NAHS. No significant differences in functional outcomes with labral repair vs debridement.
Fontana <sup>12</sup>	Statistically improved mHSS for AMIC vs microfracture at 6 months and 2, 3, 4, and 5 years. Outcomes better for AMIC regardless of the size of the lesion ( $<4 \text{ cm}^2$ vs $>4 \text{ cm}^2$ ).
Fontana <sup>11</sup>	Statistically significant improvement in mHHS when ACI technique was used compared with debridement at all time points from 6 months postoperatively to 5 years ( $P < .001$ ).
Körsmeier <sup>19</sup>	Significantly improved scores compared with preoperative levels for NAHS and WOMAC at 6 weeks postoperatively and “last follow-up” (mean, 16.1 months; range, 9.5-28.8 months).
LaFrance <sup>20</sup>	No significant difference in NAHS, mHHS, and HOS at any time point up to 12 months after surgery between the PRP and placebo cohorts.
Mancini <sup>24</sup>	Significant improvement in mHHS at 6 months compared with preoperative score in both groups. Improvement maintained to 5 years. No statistical difference seen between AMIC vs ACI regardless of defect size.
Mardones <sup>25</sup>	Statistically significant improvements in preoperative to postoperative scores (mHHS [mean improvement 27], WOMAC [mean improvement 23], Vail Hip Score [mean improvement 26], and VAS [from 6 to 2]) at final follow-up (mean, 24 months; range, 13-36 months; $P < .05$ ).
Rafols <sup>40</sup>	No statistical difference in mHHS between the study group (PRP) and control group at 3, 6, and 24 months. Improved pain at 48 hours after surgery in the PRP group ( $P < .05$ ). 100% labral integration in PRP group vs 94% in control seen on MRI at 6 months ( $P = .08$ ). No effusion seen on MRI at 6 months in 37% of PRP group vs 21% of control ( $P < .05$ ).
Redmond <sup>41</sup>	No difference in HOS or NAHS at any time point between study group and control group. No difference in pain at 3 months postoperatively. Higher pain scores at 2 years in study group vs control at 2 years (3.4 vs 2.5; $P = .005$ ).

<sup>a</sup>ACI, autologous chondrocyte implantation; AMIC, autologous matrix-induced chondrogenesis; HOS, Hip Outcome Score; mHHS, modified Harris Hip Score; MRI, magnetic resonance imaging; NAHS, Nonarthritic Hip Score; PRP, platelet-rich plasma; SF-36, 36-Item Short Form Health Survey; VAS, visual analog scale; WOMAC, Western Ontario and McMaster Universities Arthritis Index.

scores until final follow-up. Fontana and de Girolamo<sup>12</sup> compared AMIC with microfracture and noted that the microfracture cohort improved up to the 1-year follow-up but that results deteriorated from 1 to 5 years. However, this was not the case for the AMIC cohort, which showed maintained results. Furthermore, the authors stratified modified Harris Hip Scores into critical values according to treatment and chondral lesion size and found that defects larger than  $4 \text{ cm}^2$  correlated with a 2-fold incidence of low scoring in the microfracture group but did not correlate with low scoring in the AMIC cohort.

No study using adjuvant PRP to treat labral tears showed improvements in postoperative outcome measures versus well-matched, controlled cohorts. Redmond et al<sup>41</sup> also included other hip-related conditions, such as chondral lesions, gluteus medius tears, and ligament teres tears, whereas LaFrance et al<sup>20</sup> included patients who underwent psoas muscle release and/or microfracture, and therefore the 3 studies using PRP are not directly comparable. Furthermore, we noted significant differences in the PRP concentrations used. This variability in the delivered concentration of biologic formulations among studies in the current literature has already been emphasized by the authors of this study in previous reviews.<sup>7,31,42</sup> Murray et al<sup>32</sup> also highlighted the importance of selecting the correct formula of biologic most suited to the microenvironment being treated. The contrasting results in our review between PRP and ACI/AMIC may be due to delivery of subtherapeutic

concentrations of PRP, mismatches between the microenvironment and the formulation, or both. Furthermore, no study routinely used postoperative interval arthroscopy to evaluate the macroscopic change in chondral lesion, and previous evidence has shown that PRP is relatively ineffective within the hip joint, particularly in cases of chondral lesions.<sup>22</sup>

In our review, the study analyzing BM-MSCs was the most complete in reporting biologic preparation, classification, and concentration details. Details such as these have previously been recommended by an expert consensus as being pertinent to the interpretation of studies involving biologics, and minimal reporting guidelines have been established.<sup>30</sup> Mardones et al<sup>25</sup> did not compare their results of intra-articular injection of BM-MSCs to a control cohort but did show significant improvements from preoperative to postoperative functional scores at a mean follow-up of 24 months. Delivery of the cells was staggered at 3 intervals, 1 week apart. This timing of delivery has previously been shown to be effective in animal studies.<sup>33</sup>

There were 2 studies that compared conversion rates with total hip replacement between a biologics cohort and a control cohort. Both studies reported higher rates of THA in the nonbiologics cohort. In contrast, Redmond et al<sup>41</sup> reported higher rates of reoperation in the biologics cohort but did not power their study to detect differences in either reoperation rate or conversion to THA. Fontana and de Girolamo<sup>12</sup> reported that all patients undergoing THA during their follow-up had recognized

risk factors for the development of degenerative change, such as cam lesions with deep chondral lesions and lesions with a diameter greater than 4 cm<sup>2</sup>.

Other outcome measures used to determine effectiveness of biologic treatment were the postoperative presence of an effusion on MRI scanning and the appearance of the chondral lesion on second-look arthroscopy. Rafols et al<sup>40</sup> reported a lack of hip joint effusion in 36.7% of the PRP group compared with 21.1% of the placebo group at 6-month follow-up on MRI scanning. Körsmeier et al<sup>19</sup> performed arthroscopy on 2 patients at 5 and 8 months after ACI and reported hyaline-like cartilage in the area of previous implantation.

Elements of homogeneity were noted among the included studies in our review. In particular, these included a similar preoperative osteoarthritis status and similar severity of chondral injuries, with most studies using grade 3 or 4 on the Outerbridge classification. Despite this, marked differences were seen, such as variations in lesions, the treatment methods used (and reported), the concentration of PRP, the timing of delivery, the outcome measures used, the presence of a control group, and follow-up time points.

## Limitations

This review must be interpreted with recognition of its limitations. Included were 3 low-level case series that simply compared pre- and postoperative outcome measures. Given the well-recognized placebo effect in orthopaedic surgery studies, these types of studies must be interpreted with caution.<sup>46</sup> Furthermore, only one level 1, randomized controlled trial was included in our review, and it did not report mid- to long-term follow-up. Average follow-up in this review was 20.9 months, and therefore overall failure rates and conversion to THA may be underestimated.

A variety of lesions were treated within each study, and some studies did not clearly report the exact surgical interventions performed alongside the use of the biologic agent. These details are important to include if the true efficacy of the biologic intervention is to be determined. The severity of osteoarthritis and the classification systems used to measure it varied between studies, with 1 study including patients with Tönnis grade 3 osteoarthritis. Furthermore, it is recognized that advancing age limits the function of stem cells.<sup>34</sup> All studies in this review included patients with a mean age older than 30 years, and 2 studies included patients with a mean age older than 40. There was paucity in the reporting of biologic preparation and concentration between studies. When these aspects were reported, variation was seen in the concentration used and timing of delivery. Finally, a relatively small number of studies were included in this review, and 3 of the studies were performed in a single center, with possible crossover in patients among those studies. Despite these limitations, the current review accurately outlines the current state of the existing literature in this area.

## CONCLUSION

The current literature regarding biologic adjuncts in hip arthroscopy is varied in quality, with only one level 1 study. The use of ACI or AMIC for medium-sized chondral lesions showed promising results in individual studies; however, these studies were of lower quality. To enable comparisons among future studies, investigators must ensure accuracy in the reporting of the biologic preparations and formulations used and homogeneity in the type and severity of pathologic condition treated.

## REFERENCES

1. Agricola R, Heijboer MP, Bierma-Zeinstra SM, Verhaar JA, Weinans H, Waarsing JH. Cam impingement causes osteoarthritis of the hip: a nationwide prospective cohort study (CHECK). *Ann Rheum Dis*. 2013;72:918-923.
2. Agricola R, Waarsing JH, Arden NK, et al. Cam impingement of the hip: a risk factor for hip osteoarthritis. *Nat Rev Rheumatol*. 2013;9:630-634.
3. Balasubramaniam U, Dissanayake R, Annabell L. Efficacy of platelet-rich plasma injections in pain associated with chronic tendinopathy: a systematic review. *Phys Sportsmed*. 2015;43:253-261.
4. Bardakos NV, Villar RN. The ligamentum teres of the adult hip. *J Bone Joint Surg Br*. 2009;91:8-15.
5. Basad E, Ishaque B, Bachmann G, Sturz H, Steinmeyer J. Matrix-induced autologous chondrocyte implantation versus microfracture in the treatment of cartilage defects of the knee: a 2-year randomised study. *Knee Surg Sports Traumatol Arthrosc*. 2010;18:519-527.
6. Chahal J, Van Thiel GS, Mall N, et al. The role of platelet-rich plasma in arthroscopic rotator cuff repair: a systematic review with quantitative synthesis. *Arthroscopy*. 2012;28:1718-1727.
7. Chahla J, Cinque ME, Piuze NS, et al. A call for standardization in platelet-rich plasma preparation protocols and composition reporting: a systematic review of the clinical orthopaedic literature. *J Bone Joint Surg Am*. 2017;99:1769-1779.
8. Fickert S, Schattenberg T, Niks M, Weiss C, Thier S. Feasibility of arthroscopic 3-dimensional, purely autologous chondrocyte transplantation for chondral defects of the hip: a case series. *Arch Orthop Trauma Surg*. 2014;134:971-978.
9. Figueroa D, Figueroa F, Calvo R, Vaisman A, Ahumada X, Arellano S. Platelet-rich plasma use in anterior cruciate ligament surgery: systematic review of the literature. *Arthroscopy*. 2015;31:981-988.
10. Fitzpatrick J, Bulsara M, Zheng MH. The effectiveness of platelet-rich plasma in the treatment of tendinopathy: a meta-analysis of randomized controlled clinical trials. *Am J Sports Med*. 2017;45:226-233.
11. Fontana A, Bistolfi A, Crova M, Rosso F, Massazza G. Arthroscopic treatment of hip chondral defects: autologous chondrocyte transplantation versus simple debridement—a pilot study. *Arthroscopy*. 2012;28:322-329.
12. Fontana A, de Girolamo L. Sustained five-year benefit of autologous matrix-induced chondrogenesis for femoral acetabular impingement-induced chondral lesions compared with microfracture treatment. *Bone Joint J*. 2015;97:628-635.
13. Gosens T, Peerbooms JC, van Laar W, den Ouden BL. Ongoing positive effect of platelet-rich plasma versus corticosteroid injection in lateral epicondylitis: a double-blind randomized controlled trial with 2-year follow-up. *Am J Sports Med*. 2011;39:1200-1208.
14. Govender S, Csimma C, Genant HK, et al. Recombinant human bone morphogenetic protein-2 for treatment of open tibial fractures: a prospective, controlled, randomized study of four

- hundred and fifty patients. *J Bone Joint Surg Am.* 2002;84:2123-2134.
15. Griffin DR, Dickenson EJ, O'Donnell J, et al. The Warwick agreement on femoroacetabular impingement syndrome (FAI syndrome): an international consensus statement. *Br J Sports Med.* 2016;50:1169-1176.
  16. Griffin DR, Dickenson EJ, Wall PDH, et al. Hip arthroscopy versus best conservative care for the treatment of femoroacetabular impingement syndrome (UK FASHIoN): a multicentre randomised controlled trial. *Lancet.* 2018;391:2225-2235.
  17. Griffin M, Iqbal SA, Bayat A. Exploring the application of mesenchymal stem cells in bone repair and regeneration. *J Bone Joint Surg Br.* 2011;93:427-434.
  18. Hurley ET, Lim Fat D, Moran CJ, Mullett H. The efficacy of platelet-rich plasma and platelet-rich fibrin in arthroscopic rotator cuff repair: a meta-analysis of randomized controlled trials. *Am J Sports Med.* 2019;47:753-761.
  19. Körsmeier K, Classen T, Kamminga M, Rekowski J, Jager M, Landgraeber S. Arthroscopic three-dimensional autologous chondrocyte transplantation using spheroids for the treatment of full-thickness cartilage defects of the hip joint. *Knee Surg Sports Traumatol Arthrosc.* 2016;24:2032-2037.
  20. LaFrance R, Kenney R, Giordano B, Mohr K, Cabrera J, Snibbe J. The effect of platelet enriched plasma on clinical outcomes in patients with femoroacetabular impingement following arthroscopic labral repair and femoral neck osteoplasty. *J Hip Preserv Surg.* 2015;2:158-163.
  21. LaPrade RF, Dragoo JL, Koh JL, Murray IR, Geeslin AG, Chu CR. AAOS research symposium updates and consensus: biologic treatment of orthopaedic injuries. *J Am Acad Orthop Surg.* 2016;24:e62-e78.
  22. Le ADK, Enweze L, DeBaun MR, Dragoo JL. Current clinical recommendations for use of platelet-rich plasma. *Curr Rev Musculoskelet Med.* 2018;11:624-634.
  23. Liddle AD, Rodriguez-Merchan EC. Platelet-rich plasma in the treatment of patellar tendinopathy: a systematic review. *Am J Sports Med.* 2015;43:2583-2590.
  24. Mancini D, Fontana A. Five-year results of arthroscopic techniques for the treatment of acetabular chondral lesions in femoroacetabular impingement. *Int Orthop.* 2014;38:2057-2064.
  25. Mardones R, Via AG, Rivera A, et al. Arthroscopic treatment of femoroacetabular impingement in patients older than 60 years. *Muscles Ligaments Tendons J.* 2016;6:397-401.
  26. Miller LE, Parrish WR, Roides B, Bhattacharyya S. Efficacy of platelet-rich plasma injections for symptomatic tendinopathy: systematic review and meta-analysis of randomised injection-controlled trials. *BMJ Open Sport Exerc Med.* 2017;3:e000237.
  27. Mishra AK, Skrepnik NV, Edwards SG, et al. Efficacy of platelet-rich plasma for chronic tennis elbow: a double-blind, prospective, multicenter, randomized controlled trial of 230 patients. *Am J Sports Med.* 2014;42:463-471.
  28. Mohal JS, Tailor HD, Khan WS. Sources of adult mesenchymal stem cells and their applicability for musculoskeletal applications. *Curr Stem Cell Res Ther.* 2012;7:103-109.
  29. Moher D, Liberati A, Tetzlaff J, Altman DG; PRISMA Group. Preferred Reporting Items for Systematic Reviews and Meta-Analyses: the PRISMA statement. *J Clin Epidemiol.* 2009;62:1006-1012.
  30. Murray IR, Geeslin AG, Goudie EB, Petrigliano FA, LaPrade RF. Minimum information for studies evaluating biologics in orthopaedics (MIBO): platelet-rich plasma and mesenchymal stem cells. *J Bone Joint Surg Am.* 2017;99:809-819.
  31. Murray IR, Robinson PG, West CC, et al. Reporting standards in clinical studies evaluating bone marrow aspirate concentrate: a systematic review. *Arthroscopy.* 2018;34:1366-1375.
  32. Murray IR, Safran MR, LaPrade RF. Biologics in orthopaedics. *Bone & Joint 360.* 2019;7(6):2-8.
  33. Nam HY, Karunanithi P, Loo WC, et al. The effects of staged intra-articular injection of cultured autologous mesenchymal stromal cells on the repair of damaged cartilage: a pilot study in caprine model. *Arthritis Res Ther.* 2013;15:R129.
  34. Narbonne P. The effect of age on stem cell function and utility for therapy. *Cell Med.* 2018;10:2155179018773756.
  35. Obaid H, Connell D. Cell therapy in tendon disorders: what is the current evidence? *Am J Sports Med.* 2010;38:2123-2132.
  36. Palmer AJR, Ayyar Gupta V, Fernquest S, et al. Arthroscopic hip surgery compared with physiotherapy and activity modification for the treatment of symptomatic femoroacetabular impingement: multicentre randomised controlled trial. *BMJ.* 2019;364:l185.
  37. Papavasiliou A, Yercan HS, Koukoulis N. The role of hip arthroscopy in the management of osteonecrosis. *J Hip Preserv Surg.* 2014;1:56-61.
  38. Piuze NS, Chahla J, Jiandong H, et al. Analysis of cell therapies used in clinical trials for the treatment of osteonecrosis of the femoral head: a systematic review of the literature. *J Arthroplasty.* 2017;32:2612-2618.
  39. Piuze NS, Chahla J, Schrock JB, et al. Evidence for the use of cell-based therapy for the treatment of osteonecrosis of the femoral head: a systematic review of the literature. *J Arthroplasty.* 2017;32:1698-1708.
  40. Rafols C, Monckeberg JE, Numair J, Botello J, Rosales J. Platelet-rich plasma augmentation of arthroscopic hip surgery for femoroacetabular impingement: a prospective study with 24-month follow-up. *Arthroscopy.* 2015;31:1886-1892.
  41. Redmond JM, Gupta A, Stake CE, Hammarstedt JE, Finch NA, Domb BG. Clinical results of hip arthroscopy for labral tears: a comparison between intraoperative platelet-rich plasma and bupivacaine injection. *Arthroscopy.* 2015;31:445-453.
  42. Robinson PG, Murray IR, West CC, et al. Reporting of mesenchymal stem cell preparation protocols and composition: a systematic review of the clinical orthopaedic literature. *Am J Sports Med.* 2019;47:991-1000.
  43. Saris D, Price A, Drogset JO, et al. SUMMIT prospective, randomized, controlled trial: response rates to matrix-induced autologous chondrocyte implant (MACI) versus microfracture (MFx) by lesion characteristics. *Orthop J Sports Med.* 2013;1(4 suppl):2325967113S2325900029.
  44. Spiker AM, Degen RM, Camp CL, Coleman SH. Arthroscopic psoas management: techniques for psoas preservation and psoas tenotomy. *Arthrosc Tech.* 2016;5:e1487-e1492.
  45. Vavken P, Sadoghi P, Murray MM. The effect of platelet concentrates on graft maturation and graft-bone interface healing in anterior cruciate ligament reconstruction in human patients: a systematic review of controlled trials. *Arthroscopy.* 2011;27:1573-1583.
  46. Wartolowska K, Judge A, Hopewell S, et al. Use of placebo controls in the evaluation of surgery: systematic review. *BMJ.* 2014;348:G3253.

## APPENDIX

TABLE A1  
Search Term Combinations

Search	Search Terms
1	(“hip”[MeSH Terms] OR “hip”[All Fields]) “femoroacetabular”[All Fields] OR “impingement”[All Fields] OR (“arthroscopy”[MeSH Terms] OR “arthroscopy”[All Fields]) AND (“platelet-rich plasma”[MeSH Terms] OR (“platelet-rich”[All Fields] AND “plasma”[All Fields]) OR “platelet-rich plasma”[All Fields] OR (“platelet”[All Fields] AND “rich”[All Fields] AND “plasma”[All Fields]) OR “platelet rich plasma”[All Fields])
2	(“hip”[MeSH Terms] OR “hip”[All Fields]) “femoroacetabular”[All Fields] OR “impingement”[All Fields] OR (“arthroscopy”[MeSH Terms] OR “arthroscopy”[All Fields]) AND (“mesenchymal stem cells”[MeSH Terms] OR (“mesenchymal”[All Fields] AND “stem”[All Fields] AND “cells”[All Fields]) OR “mesenchymal stem cells”[All Fields])
3	(“hip”[MeSH Terms] OR “hip”[All Fields]) “femoroacetabular”[All Fields] OR “impingement”[All Fields] OR (“arthroscopy”[MeSH Terms] OR “arthroscopy”[All Fields]) AND (“bone marrow”[MeSH Terms] OR (“bone”[All Fields] AND “marrow”[All Fields]) OR “bone marrow”[All Fields]) AND aspirate [All Fields] AND concentrate[All Fields]
4	(“hip”[MeSH Terms] OR “hip”[All Fields]) “femoroacetabular”[All Fields] OR “impingement”[All Fields] (“arthroscopy”[MeSH Terms] OR “arthroscopy”[All Fields]) AND (“intercellular signalling peptides and proteins”[MeSH Terms] OR (“intercellular”[All Fields] AND “signalling” [All Fields] AND “peptides”[All Fields] AND “proteins”[All Fields]) AND “intercellular signalling peptides and proteins”[All Fields] AND (“growth”[All Fields] AND “factors”[All Fields]) AND “growth factors”[All Fields])
5	(“hip”[MeSH Terms] OR “hip”[All Fields]) AND “femoroacetabular”[All Fields] OR “impingement”[All Fields] OR (“arthroscopy”[MeSH Terms] OR “arthroscopy”[All Fields]) AND (“hyaluronic acid”[MeSH Terms] OR (“hyaluronic”[All Fields] AND “acid”[All Fields]) OR “hyaluronic acid”[All Fields])
6	(“hip”[MeSH Terms] OR “hip”[All Fields]) AND “femoroacetabular”[All Fields] OR “impingement”[All Fields] OR (“arthroscopy”[MeSH Terms] OR “arthroscopy”[All Fields]) AND autologous[All Fields] AND (“chondrocytes”[MeSH Terms] OR “chondrocytes”[All Fields] OR “chondrocyte”[All Fields]) AND (“embryo implantation”[MeSH Terms] OR (“embryo”[All Fields] AND “implantation”[All Fields]) OR “embryo implantation”[All Fields] OR “implantation”[All Fields])